



www.kjoonline.org

MRI and NLS-diagnostics of ankle joint damages

Nesterov VI¹, Vesnin AY¹, Koltsova MP

Institute of Practical
Psychophysics, Omsk,
Russia

¹ Academic of Academy
of Medical and Technical
Sciences

Correspondence should
be sent to:
v.i.nesterov@inbox.ru

Ankle joint damages is urgent medical and social problem according to its prevalence, loss of working time, material cost of treatment and covering of temporary disability and also by frequent unfavorable outcomes.

Main reasons of consulting a traumatologist are damages of tendo-ligamentous apparatus of this area. Due to this fact dominating role of medical visualisation in diagnostics of ankle joints mechanical damages seems to be obvious. Feature of combined evaluation of musculoskeletal system grants magnetic-resonance imaging (MRI) advantage over roentgenological examination in diagnostics of tendo-ligamentous apparatus damages. However low spreading of magnetic-resonance tomographs and high cost of examination considerably limit application of this method in search of ankle joint damages.

Non-linear diagnostics(NLS) based on bioresonance method may become an alternative method in diagnosis of musculoskeletal system pathology. Advantages of NLS-method are simplicity, availability, high information value and relatively low price. Taking into consideration complex structure of ankle joint and foot, easiness of poly-projecting virtual examination of extremity seems to be quite important issue. Possibility of microscanning, contactless atraumatic examination which may be repeated many times provided priority of NLS-graphy among methods of medical visualisation of ankle joint and foot damages.

STUDY TECHNIQUE

NLS-research of ankle joint was carried out with "Metatron"-4025 system with software that allows three-dimensional visualisation of extremities.

Virtual examinations were started from evaluation of anterior part of ankle joint. Afterward were evaluated:

- muscles tendons: tibialis anterior, extensor hallucis longus, extensor digitorum longus, peroneus longus è brevis, posterior tibialis, flexor hallucis longus, flexor digitorum longus;
- Achilles tendon;
- Achilles bursa;
- Ligaments: tibiofibulare anterius, talofibulare anterius, calcaneofibulare, deltoideum;
- Plantar aponeurosis.

Evaluation of tendons and ligaments were carried out in three orthogonal projections. To confirm detected changes we compared with the contralateral part. Method of three-dimensional panoramic scanning of tendons considerably increases demonstrative character of studies.

During scanning of tendon we evaluated its structure, outlines, transition to muscular tissue and chromogeneity at dynamic monitoring. NLS-picture of tendons is based on their histological structure.

Tendons consist of long collagenous fibers and at microscans, in normal condition, they look like homogeneous, hypochromogenic fibrillar structures surrounded by low-chromogenic line (synovial membrane).

At NLS-pictures ligaments in normal condition look like hypochromogenic structures in comparison to surrounding soft tissues. Due to their small size, majority of ankle joint and foot ligaments are not visualised at virtual picture. Plantar aponeurosis has homogeneous structure with insignificantly marked fibrillar pattern.

Hyaline cartilage of ankle joint in normal condition is presented, as a rule, as moderately chromogenic linear structure, adjoining hypochromogenic cortical layer of a bone.

Available online at
www.kjoonline.org

Quick response code



Kerala Journal of
Orthopaedics
2013;26(1):67-69

© Kerala Journal of Orthopaedics

METHODS

During analysis of virtual NLS-picture of ankle joint anterior part we see visualized tendons of anterior tibial muscle (m. tibialis anterior), long extensor muscle of fingers (m. extensor digitorum longus) and tendon of long extensor muscle of toe (m. extensor hallucis longus). Tendon of anterior tibial muscle (m. tibialis anterior) is located most medially of all; it is twice thicker than tendon of long extensor muscle of toe (m. extensor digitorum longus). To study anterior talofibular ligament (talofibulae anterioris) we identified cortical layers of shin bone and fibular bone; between them ligament fibers are visualised.

In lateral projection at three-dimensional picture we analyzed tendons of short and long peroneal muscles (m. peroneus longus et brevis). Tendons of short and long peroneal muscles are located behind lateral malleolus. Tendon of short peroneal muscle adjoins cortical layer of ankle and located in front of long peroneal muscles tendon. Tendon of short peroneal muscle can be traced down to basis of 5th metatarsal bone at plantar side. Long peroneal muscles tendon is visualized down to attachment to medium cuneiform bone and 1st metatarsal bone at plantar side.

Anterior talofibular ligament (lig. talofibulae anterioris) is visualized at NLS-picture between anterior edge of lateral malleolus and ankle bone. Fibers of calcaneo fibular ligament (lig. calcaneofibulare) are detected from external surface of lateral malleolus and going downwards and backwards they attach to lateral surface of heel bone.

Achilles tendon is studied from place of attachment to heel bone until place of transition to gastrocnemius muscle.

Tendons damages

Three-dimensional visualization of tendons' fibrillar structure at microscans is a distinctive feature of NLS-research in comparison with other methods of radiodiagnostics, including MRI.

The most frequent form of ankle joint and foot tendons traumas is tendosynovitis. It makes up more than 70% in structure of mechanical damages. At the same time comparative analysis of various methods of radiodiagnostics demonstrates maximum efficiency of NLS-research in detecting of tendon sheath pathological affection.

Sensitivity of this method is almost 95%. We want to emphasize greatest demonstration efficiency of transversal scanning of tendon with various degree of scaling.

NLS-graphic semiotics of tendonitis includes abnormality of tendon's fibrillar pattern, heterogeneity of structure with

hyperchromogenic nidi (5 – 6 points according to Fleindler's scale). Hyperchromogenic nidi correspond to tendon edema and xanthomatosis. Posttraumatic tendonitis in ankle joint area is diagnosed in 10% of cases.

NLS-research is also method of choice for diagnostics of tendon ruptures, percentage of which is 20%..

At type I partial rupture microscans detect abnormalities of fibrils integrity, uneven outlines of tendon. Longitudinal ruptures, according to NLS-research data, are accompanied by appearance of hyperchromogenic fissures (5 – 6 points), oriented obliquely along tendons, which may reach surface.

At NLS-graphy of type II partial rupture microscans detect abnormalities of collagenous fibers integrity..

Type III (total rupture) according to NLS-research and other radiodiagnostics methods data is characterized by complete destruction of tendon's fibers at microscanning (6 points). However differing from radio computed tomography and magnetic-resonance imaging, NLS- research makes allows us to identify place of tendon rupture more precisely and technically easily..

Ease of NLS-examination defined prerogative of this method in diagnostics of short and long peroneal muscles' tendons damages in lateral malleolus area. Flattening of ankle incisure at abnormality of retinaculum peroneum superius may result in development of lateral group tendons subluxation. This condition appears at ankle joint bending and external rotation, and also at joint extension and internal rotation. Clinical dislocation may be manifested by rupture of collateral ligaments of lateral malleolus. Visualization of forward tendon rupture at bending and joint extension in real time mode by NLS-method allows correct formulating of diagnosis in all cases.

Damages of tendons and plantar aponeurosis

MRI slightly yields to NLS-method in diagnostics of tendons damages, because majority of them are poorly visualized by MRI. Semiotics of tendons ruptures includes the following signs: total damaging of fibers, increasing of its chromogeneity and deformation of structure at microscans in comparison with the same ligament of other extremity.

In majority of cases three-dimensional NLS-examination allows us to differentiate total and partial ruptures of tendons. Differing from MRI, NLS-examination is quite sufficient for evaluation of plantar aponeurosis condition. Information value of NLS-research and MRI in aponeurosis damage evaluation is identical. However, besides fusiform thickening, intramural and

perifocal edema, detected by MRI, NLS-examination detects hyperchromogenic fibrillar structures (6 points) at microscans and increasing of aponeurosis chromogeneity. Therefore NLS-diagnostics method is highly informative in study of ankle joint damages. It may be regarded as additional method for examination of tendo-ligamentous apparatus. In majority of cases when tendons and plantar aponeurosis are damaged, NLS-examination is adequate alternative of magnetic-resonance imaging.

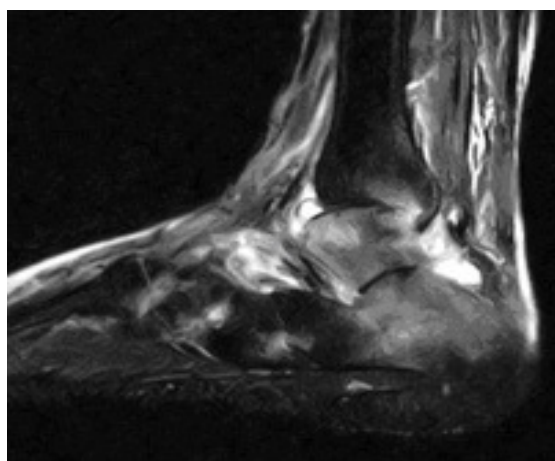


Fig. 1. MRI. Acute arthritis of ankle-joint.

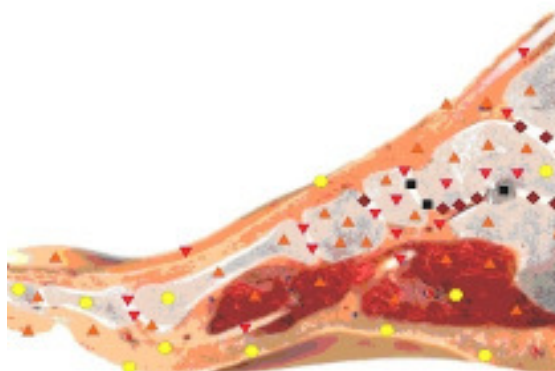


Fig. 2. NLS-graphy. Arthritis of ankle-joint

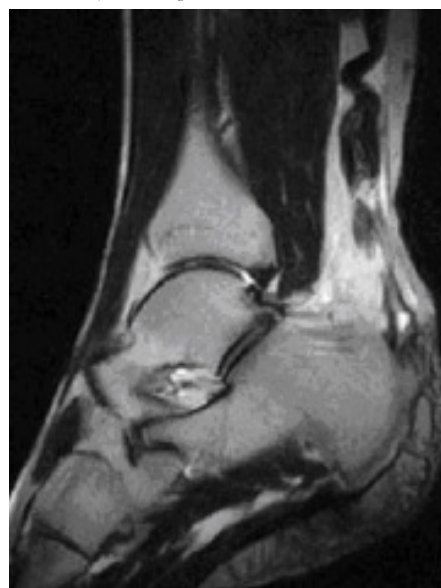

Fig. 3. MRI of ankle joint in Achilles tendon rupture

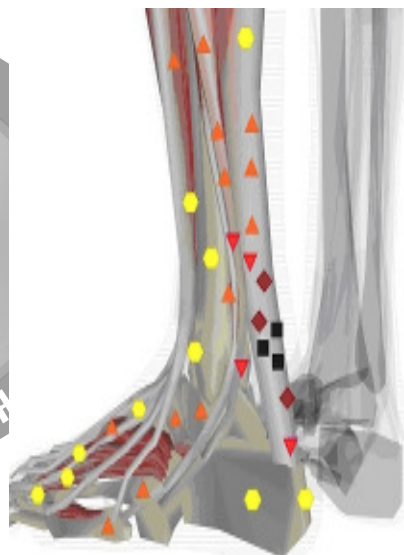


Fig. 4. NLS. Achilles tendon rupture

REFERENCES

1. Bucklein W., Vollert K., Wohlgemuth W.A., Bohndorf K. (2002) Ultrasonography of acute musculoskeletal disease. *Eur.Radiol.*, 10. 290–296.
2. Cheung Y., Rosenberg Z.S., Magee T. et al. (1992) Normal anatomy and pathologic conditions of ankle tendons: current imaging techniques. *RadioGraphics*, 12. 429-444.
3. Fessell D. (1998) US of the ankle: technique, anatomy, and diagnosis of pathologic conditions. *RadioGraphics*, 18(2). 325–340.
4. Jakobson J.A., van Holsbück M.T. (1998) Musculoskeletal ultrasonography. *Orthopedic clinic of North America*, 29(1). 140–144.
5. Krylov V.V., Shastina V.R. (1990) Ultrasound diagnostics in synostology: Review. *Medical radiology*, 35(6). 31-33.
6. Nesterov V.I. (2012) Main tendencies of NLS-technology development. *3D computer NLS-graphy* (ISBN 978-5-98597-227-6) 4-6.
7. Petrov M.S., Vesnin A.Ya, Koltsova M.P. (2012) NLS-diagnostics of ankle joint damages. *3D computer NLS-graphy*.54-56.
8. Detttersson H. Ì (1996) Guidelines on radiology. Tome1.371-2.
9. Zubarev A.V. (2002) Diagnostic ultrasound. *Musculoskeletal system*.136.

Cite this article as:

Nesterov VI, Vesnin AY, Koltsova MP. MRI and NLS-diagnostics of ankle joint damages. *Kerala Journal of Orthopaedics* 2013;26(1):67-69